



Hamilton County Coroner

The Frank P. Cleveland, M.D. Institute of Forensic Medicine, Toxicology and Criminalistics
3159 Eden Avenue, Cincinnati, Ohio 45219-2299
Office: 513-946-8700 Fax: 513-946-8727




CHRISTOPHER RHODEN, JR.

CC16-01419


OPINION

Diagnoses:

1. Multiple gunshot wounds to the head:



2. Postmortem toxicology:



OPINION

Christopher Rhoden, Jr.

PAGE 2
CC16-01419

Cause of Death: It is my opinion, based on the autopsy findings and the information available to me at the time of the autopsy that the cause of death is multiple gunshot wounds to the head.



Karen Looman, D.O.

Chief Deputy Coroner, Forensic Pathologist
Hamilton County, Ohio

7/11/2016

Date

**POSTMORTEM EXAMINATION
OF THE BODY OF
CHRISTOPHER RHODEN, JR.**

A postmortem examination of the body identified by Pike County Coroner's Office as "Christopher Rhoden Jr." is performed at the Hamilton County Coroner's Office on Sunday, April 24, 2016 at 7:03 AM by Dr. Karen Looman. [REDACTED]

HISTORY:

The decedent is a 16-year-old white male who was found deceased in his home with multiple gunshot wounds.

EXTERNAL EXAMINATION

GENERAL:

The body is that of a normally developed, well-nourished, young adult male who is 165 pounds, 70-inches in height, and appears appropriate for the stated age. [REDACTED]

[REDACTED] The scalp hair is short, straight and blonde. There is no mustache, beard or stubble. [REDACTED]

[REDACTED] The irides are blue. The mouth has native dentition. The chest has a normal anteroposterior diameter without costal margin flaring. [REDACTED]

[REDACTED] The spine is straight. The pelvis is stable to manipulation. The extremities are not edematous and are free of dysmorphic features. There are paper bags on the hands. [REDACTED]

[REDACTED] An identification toe tag within name "Christopher Rhoden" and "11/4/99" is on the left great toe.

SCARS/TATTOOS:


Multiple small white scars are on the [REDACTED] There is an irregular purple scar on the [REDACTED] A purple scar is on the [REDACTED]

MARKS OF THERAPY:

None.

EVIDENCE OF INJURY:

There are multiple gunshot wounds to the head [REDACTED]
[REDACTED] The wounds are numbered for convenience and do not indicate the order in which they were inflicted.



Other Injuries: [REDACTED]
[REDACTED] There is a scab proximal to the [REDACTED] petechial contusion distal to the left elbow. The left volar forearm has a 2-inch linear red petechial contusion. A 1/8-inch scab is on the [REDACTED] There is a 3-inch linear scab on the [REDACTED]

X-RAYS:

Films of the head and upper chest are taken.

INTERNAL EXAMINATION**SEROUS CAVITIES:**

[REDACTED] The right posterior lung surface is adherent to the chest wall. [REDACTED]

NECK ORGANS:

[REDACTED] The thyroid gland is congested and purple. Upon sectioning, there are no focal lesions. There is a thymic remnant in the anterior mediastinum.

HEART:

The heart is 365 grams. The coronary arteries arise normally and are right-sided dominant. There is no coronary artery disease. The myocardium is red, soft and without scars. The septa are intact. The foramen ovale is sealed. The left ventricular wall is concentric. The valves are thin, delicate, and unremarkable.

AORTA:

The aorta is free of fatty streaks, plaques or calcifications. There is mild, red hemolytic staining along its length.

LUNGS:

The right lung is 420 grams, and the left lung is 450 grams. [REDACTED] The mucosa is also stained dark red-purple. The lumen is free of fluid, foam or obstruction. Both lungs are normally aerated but congested. [REDACTED] There are no focal lesions.

LIVER AND GALLBLADDER:

The liver is 1,530 grams. The capsule is intact and covers a red-brown parenchyma. Upon sectioning, there are no focal lesions. The gallbladder contains 10 milliliters of green-yellow bile. There are no stones in the lumen.

SPLEEN:

The spleen is 175 grams. The capsule is intact and covers partially liquefied, dark red parenchyma. The white pulp is not visualized and there are no focal lesions.

PANCREAS:

The pancreas has mild autolytic changes but has a congested, tan, lobulated architecture without focal lesions.

ADRENAL GLANDS:

The glands have mild autolytic changes but have retained their normal yellow cortices and softened tan medullae without focal lesions.

GASTROINTESTINAL TRACT:

[REDACTED] The gastroesophageal junction and gastric mucosa are autolytic. There are no rugal folds present. The stomach contains 100 milliliters of [REDACTED]. The small and large intestines are distended with gas. The appendix is present.

KIDNEYS:

The right kidney is 130 grams, and the left kidney is 155 grams. Both capsules strip with ease from each smooth cortical surface. Upon bisection, the calyces are patent and free of stones or hydronephrosis.

BLADDER:

The bladder contains 200 milliliters of clear, yellow urine. The mucosa is light tan and unremarkable.

GENITALIA:

[REDACTED] The prostate and testicles are not examined.

BRAIN AND MENINGES:

The brain is 1,725 grams [REDACTED]. The brain is diffusely congested, slightly swollen, and red across the superior surface and deep purple across the inferior surface. [REDACTED] There are a thin layer of subdural hemorrhage [REDACTED] subarachnoid hemorrhage [REDACTED]. There are bullet perforations [REDACTED]. The leptomeninges [REDACTED] but are otherwise thin and free of purulent exudate. The cranial nerves and vessels are unremarkable. Upon sectioning, the cortical ribbon is thin and even. [REDACTED]

SKULL AND SUBGALEA:

There is [REDACTED] fracture [REDACTED]. There are [REDACTED] bullet [REDACTED].

[REDACTED]

There are [REDACTED] subgaleal hemorrhages [REDACTED]
[REDACTED]

RIBS/STERNUM:

The ribs and sternum are [REDACTED] and within normal limits.

VERTEBRAE:

The vertebrae are [REDACTED] and within normal limits.

PELVIS:

The pelvis is [REDACTED] and within normal limits.

EXTREMITIES:

The extremities have scars, scabs and [REDACTED] as previously described.

[REDACTED]

LABORATORY EXAMINATION

Laboratory examinations were ordered, and the results are attached.

07/07/2016 njb



HAMILTON COUNTY CRIME LABORATORY
The Frank P. Cleveland, M.D. Institute of Forensic Medicine, Toxicology and Criminalistics
3159 Eden Avenue, Cincinnati, Ohio 45219-2299
Crime Laboratory 513-946-8750 Fax 513-946-8772




TOXICOLOGY REPORT

SUBJECT NAME(S): Rhoden, Jr., Christopher
SUBMITTING AGENCY: Pike County Coroner

FILE #: CC16-01419
DATE REPORTED: 05/20/2016

RESULTS:



Rachel M. Hamilton

Rachel M. Hamilton
Toxicologist



Hamilton County Coroner

The Frank P. Cleveland, M.D. Institute of Forensic Medicine, Toxicology and Criminalistics
3159 Eden Avenue, Cincinnati, Ohio 45219-2299
Office: 513-946-8700 Fax: 513-946-8727




CHRISTOPHER D. RHODEN, SR.



CC16-01416

OPINION

Diagnoses:

1. Multiple gunshot wounds to the head, torso and upper extremity:







4. Postmortem toxicology



Cause of Death: It is my opinion, based on the autopsy findings and the information available to me at the time of the autopsy that the cause of death is multiple gunshot wounds to the head, torso and upper extremity.

Karen Looman, D.O.
Chief Deputy Coroner, Forensic Pathologist
Hamilton County, Ohio

7/8/2016

Date

POSTMORTEM EXAMINATION
OF THE BODY OF

CHRISTOPHER D. RHODEN, SR.

A postmortem examination of the body identified by Pike County Coroner's Office as "Christopher Rhoden, Sr." is performed at the Hamilton County Coroner's Office. A portion of the external examination was performed on Sunday, April 24, 2016 at 2:07 p.m. The rest of the external and entire internal examination was performed on Monday, April 25, 2016 at 8:30 a.m. by Dr. Karen Looman. [REDACTED]

HISTORY:

The decedent is a 40-year-old white male who was found deceased in his home with multiple gunshot wounds.

EXTERNAL EXAMINATION

GENERAL:

The body is that of a normally developed, well-nourished, adult male who is 222 pounds, 71-inches in height, and appears appropriate for the stated age. [REDACTED]

The body is cool to the touch due to refrigeration. [REDACTED]

[REDACTED] The scalp has male pattern balding and the hair is short, slightly curly, light brown and along the sides of the head. There is a gray-brown mustache, beard and stubble across the hair-bearing portions of the face. [REDACTED] inward. The sclerae are free of petechia, icterus or hemorrhage. The corneas are slightly opaque. The irides are blue. The mouth has native dentition. [REDACTED] The chest has a slightly increased anteroposterior diameter with costal margin flaring. [REDACTED]

[REDACTED] A brown mole is in the [REDACTED] The spine is straight. The pelvis is stable to manipulation. The upper extremities are not edematous. There are paper bags on the hands. The fingernails are short. The lower extremities have no dysmorphic features.

[REDACTED]

[REDACTED]



SCARS/TATTOOS:


[redacted] oval scar is on [redacted] A wide horizontal scar is in the right anterolateral chest wall. The chest wall is slightly depressed at this site. A linear scar is in the lower right chest. Two puckered, linear scars [redacted] There is a longitudinal scar between [redacted] A small scar is on [redacted]


MARKS OF THERAPY:



None.

EVIDENCE OF INJURY:

There are multiple gunshot wounds to the head, torso and upper extremity [redacted] [redacted] The gunshot wounds are numbered for convenience and do not indicate the order in which they were inflicted.







Other injuries:



X-RAYS:

Films of the head, neck, torso and upper extremities are taken.

INTERNAL EXAMINATION**SEROUS CAVITIES:**

The abdomen is free of fluid collections. There are anterior, lateral and posterior [REDACTED]. The diaphragm is strongly adherent to the anterior and superior surface of the liver. Several blue surgical sutures are identified within the adhesions. There are sutures within the lower anterior abdominal wall. Within the area of the xiphoid process is a calcified 1-inch x 4-inch fragment of soft tissue and fascia that contains blue suture material. The intestines have scant adhesions and are not oriented normally. [REDACTED]

NECK ORGANS:

[REDACTED] The thyroid gland is tan, homogeneous and free of lesions.

HEART:

The heart is 340 grams. The coronary arteries arise normally and are right-sided dominant. [REDACTED]

The left anterior descending coronary artery has focal 50, 20 and 10-percent stenoses. The circumflex coronary artery is free of disease. The myocardium is red, soft [REDACTED] and without scars. Both the right and left ventricles are mildly dilated. The left ventricular wall is approximately 1.5-centimeters in thickness. The valves are thin, delicate, and unremarkable.

AORTA:

The aorta has mild fatty streaks along its length. [REDACTED]

LUNGS:

The right lung is 480 grams, and the left lung is 260 grams. [REDACTED]

[REDACTED] There is no obstruction present. Both lungs are congested, red-black and free of aeration. [REDACTED] Upon sectioning there is minimal edema and no focal lesions present.

LIVER AND GALLBLADDER:

The liver is 1,340 grams. The capsule is intact and covers a red-brown parenchyma. [REDACTED]

[REDACTED] There are no focal lesions. The gallbladder contains 5 milliliters of green-yellow bile. A single 1.0-centimeter lobulated, black stone is identified within the lumen.

SPLEEN:

The spleen is 170 grams. The capsule is friable and covers liquefied, dark red parenchyma. The white pulp is not visualized. There are no focal lesions.

PANCREAS:

The pancreas has autolytic changes including saponification. The parenchyma is orange-brown, slightly lobulated and free of lesions.

ADRENAL GLANDS:

[REDACTED] Yellow cortices and softened brown medullae are present. No lesions are identified.

GASTROINTESTINAL TRACT:

[REDACTED] The gastroesophageal junction and gastric mucosa are autolytic. There are no rugal folds present. The stomach contains 100 milliliters of orange-tan fluid. The small and large intestines are distended with gas. [REDACTED]

[REDACTED] The appendix is not identified.

KIDNEYS:

The right kidney is 130 grams, and the left kidney is 145 grams. Both capsules strip with ease from each smooth cortical surface. [REDACTED]

[REDACTED] No perforation of the organ is present. Upon bisection, the calyces are patent and free of stones or hydronephrosis.

BLADDER:

The bladder contains 20 milliliters of clear, yellow urine. The mucosa is light tan and unremarkable.

GENTALIA:

[REDACTED] The prostate and testicles are not examined.

BRAIN AND MENINGES:

The brain is 1,425 grams and has a congested, red-gray appearance [REDACTED] The parenchyma is soft and friable. There is no epidural or subdural hemorrhage. The brain has diffuse red subarachnoid hemorrhage. [REDACTED]

[REDACTED] The cranial nerves and vessels are disrupted and not identifiable. Upon sectioning, the cortical ribbon is thin and even. There is no intraparenchymal hemorrhage or lesions identified. The cerebellum is soft and friable. [REDACTED]

[REDACTED] There are purple linear hemorrhages throughout the pons. [REDACTED]

SKULL AND SUBGALEA:

There is [REDACTED] bone fracture [REDACTED]

[REDACTED] fractures.

[REDACTED] fractured.

[REDACTED] hemorrhage.

RIBS/STERNUM:

[REDACTED] The sternum is unremarkable.

VERTEBRAE:

There is a fracture [REDACTED]

PELVIS:

The pelvis is [REDACTED] and within normal limits.

EXTREMITIES:

[REDACTED]

[REDACTED]

LABORATORY EXAMINATION

Laboratory examinations were ordered, and the results are attached.

07/07/2016 njb



HAMILTON COUNTY CRIME LABORATORY
The Frank P. Cleveland, M.D. Institute of Forensic Medicine, Toxicology and Criminalistics
3159 Eden Avenue, Cincinnati, Ohio 45219-2299
Crime Laboratory 513-946-8750 Fax 513-946-8772




TOXICOLOGY REPORT

SUBJECT NAME(S): Rhoden, Sr., Christopher
SUBMITTING AGENCY: Pike County Coroner

FILE #: C27601416
DATE REPORTED: 05/20/2016

RESULTS:



Rachel M. Hamilton

Rachel M. Hamilton
Toxicologist



Hamilton County Coroner

The Frank P. Cleveland, M.D. Institute of Forensic Medicine, Toxicology and Criminalistics
3150 Eden Avenue, Cincinnati, Ohio 45219-2299
Office: 513-946-8700 Fax: 513-946-8727




CLARENCE FRANKLIN RHODEN

CC16-01417

OPINION

Diagnoses:

1. Multiple gunshot wounds to the head:




OPINION

Clarence Franklin Rhoden

PAGE 2
CC16-01417

2. Postmortem toxicology:



Cause of Death: It is my opinion, based on the autopsy findings and the information available to me at the time of the autopsy that the cause of death is multiple gunshot wounds to the head.

Handwritten signature of Karen Looman in cursive script.

Karen Looman, D.O.
Chief Deputy Coroner, Forensic Pathologist
Hamilton County, Ohio

7/11/2016

Date

POSTMORTEM EXAMINATION
OF THE BODY OF

CLARENCE FRANKLIN RHODEN

A postmortem examination of the body identified by Pike County Coroner's Office as "Clarence Rhoden" is performed at the Hamilton County Coroner's Office on Sunday, April 24, 2016 at 8:36 a.m. by Dr. Karen Looman. [REDACTED]

HISTORY:

The decedent is a 20-year-old white male who was found deceased [REDACTED] with gunshot wounds to the head.

EXTERNAL EXAMINATION

GENERAL:

The body is that of a normally developed, well-nourished, adult male who is 260 pounds, 74-inches in height, and appears appropriate for the stated age. The body mass index (BMI) is 33.4 kilograms per meter squared with the normal range between 18.5 and 24.9 kilograms per meter squared. [REDACTED]

The body is cool to the touch due to refrigeration. [REDACTED]

The scalp hair is short, shaved and medium brown. There is a light brown beard, scant mustache and stubble across the hair-bearing portions of the face. [REDACTED]

[REDACTED] The irides are brown. There is mild acne across the cheeks. The mouth has native dentition. The chest has a normal anteroposterior diameter without costal margin flaring. There is a brown mole in the [REDACTED]. The abdomen is protuberant with striae around the waistline. [REDACTED] The penis is [REDACTED]

The spine is straight. The pelvis is stable to manipulation. The upper extremities are not edematous. There are brown paper bags covering the hands. The fingernails are short and to the quick. The lower extremities have no dysmorphic features. There is a tag with "Clarence Rhoden" and "BCI CS 0440" on the right great toe. [REDACTED]

SCARS/TATTOOS:

There is a single round scar on the right upper chest. A small scar is above the [REDACTED]. There are multiple round [REDACTED] scars in the [REDACTED]. The right lower lateral back has linear scars. [REDACTED] multiple linear scars along its length. [REDACTED] has multiple scars. There is an oblique linear scar on the [REDACTED] and a pink scar on the [REDACTED]. [REDACTED]


There are no tattoos present.

MARKS OF THERAPY:

None.

EVIDENCE OF INJURY:

There are multiple gunshot wounds to the head [REDACTED] The gunshot wounds are numbered for convenience and do not indicate the order in which they were inflicted.



X-RAYS:

Films of the head and upper chest are taken.

GASTROINTESTINAL TRACT:

The tongue is atraumatic. The esophagus is patent [REDACTED] The gastroesophageal junction and gastric mucosa are autolytic. There are no rugal folds present. The stomach contains 500 milliliters of [REDACTED] The small and large intestines are distended with gas. [REDACTED] There are staples on the cecum wall.

KIDNEYS:

The right kidney is 200 grams, and the left kidney is 170 grams. Both capsules strip with ease from each smooth cortical surface. Upon bisection, the calyces are patent and free of stones or hydronephrosis.

BLADDER:

The bladder contains 150 milliliters of clear, yellow urine. The mucosa is light tan and unremarkable.

GENITALIA:

[REDACTED] The prostate and testicles are not examined.

BRAIN AND MENINGES:

The brain is 1,460 grams and is soft [REDACTED] The brain has a generalized red-gray appearance. There is no epidural hemorrhage. There are thin films of purple subdural

[REDACTED]
Upon sectioning, the cortical ribbon is thin and even.

[REDACTED] The brain stem and cerebellum are congested and red but free of purple

[REDACTED] No other lesions are identified.

SKULL AND SUBGALEA:

[REDACTED]

RIBS/STERNUM:

The ribs and sternum are [REDACTED] and within normal limits.

VERTEBRAE:

The vertebrae are [REDACTED] and within normal limits.

PELVIS:

The pelvis is [REDACTED] and within normal limits.

EXTREMITIES:

The extremities have [REDACTED] as previously described.

LABORATORY EXAMINATION

Laboratory examinations were ordered, and the results are attached.

07/07/2016 njb



HAMILTON COUNTY CRIME LABORATORY
The Frank P. Cleveland, M.D. Institute of Forensic Medicine, Toxicology and Criminalistics
3159 Eden Avenue, Cincinnati, Ohio 45219-2299
Crime Laboratory 513-946-8750 Fax 513-946-8772




TOXICOLOGY REPORT

SUBJECT NAME(S): Rhoden, Clarence
SUBMITTING AGENCY: Pike County Coroner

FILE #: CC16-01417
DATE REPORTED: 05/20/2016

RESULTS:



Rachel M. Hamilton

Rachel M. Hamilton
Toxicologist



Hamilton County Coroner

The Frank P. Cleveland, M.D. Institute of Forensic Medicine, Toxicology and Criminalistics
3159 Eden Avenue, Cincinnati, Ohio 45219-2299
Office: 513-946-8700 Fax: 513-946-8727




DANA RHODEN


CC16-01420

OPINION

Diagnoses:

1. Multiple gunshot wounds to the head and neck:





2. Postmortem toxicology:



Cause of Death: It is my opinion, based on the autopsy findings and the information available to me at the time of the autopsy that the cause of death is multiple gunshot wounds to the head and neck.

Karen Looman, D.O.
Chief Deputy Coroner, Forensic Pathologist
Hamilton County, Ohio

7/11/2016

Date

POSTMORTEM EXAMINATION
OF THE BODY OF

DANA RHODEN

A postmortem examination of the body identified by Pike County Coroner's Office as "Dana Rhoden" is performed at the Hamilton County Coroner's Office on Saturday, April 23, 2016 at 1:30 p.m. by Dr. Karen Looman. [REDACTED]

HISTORY:

The decedent is a 37-year-old white female who was found deceased in her home with gunshot wounds.

EXTERNAL EXAMINATION

GENERAL:

The body is that of a normally developed, obese, adult female who is 215 pounds, 66-inches in height, and appears appropriate for the stated age. The body mass index (BMI) is 34.7 kilograms per meter squared with the normal range between 18.5 and 24.9 kilograms per meter squared. The body is cool to the touch due to refrigeration. [REDACTED]

The scalp hair is short, slightly curled and light to dark brown. [REDACTED]

[REDACTED] The irides are brown. The mouth has native dentition. The chest has a normal anteroposterior diameter without costal margin flaring. The breasts are free of palpable masses. The abdomen is protuberant with pannus folds and striae around the waistline. The external genitalia are normal for an adult female. The spine is straight. The pelvis is stable to manipulation. The extremities are not edematous and are free of dysmorphic features. Both hands are covered with brown paper bags. The fingernails are short and clean. [REDACTED]

[REDACTED] An identification tag within name "Dana Rhoden" is on the right great toe.

SCARS/TATTOOS:

[REDACTED] has a series of interrupted longitudinal scars extending from the [REDACTED] to the [REDACTED]. There is a linear scar along the [REDACTED]. Three short straight scars are across the left knee.

[REDACTED] has multicolored [REDACTED] with [REDACTED] lines. [REDACTED] surrounded by the words [REDACTED] multicolored [REDACTED] flower. The [REDACTED] wrist has the words [REDACTED] in an [REDACTED] design. The left volar wrist has [REDACTED] with two stars. [REDACTED]


[REDACTED] has multicolored flowers and a red skull. There is a tattoo of a [REDACTED]
[REDACTED] The dorsum of the [REDACTED] The [REDACTED] leg
has a multicolored butterfly and the word [REDACTED] with a heart on the dorsum of the [REDACTED]

MARKS OF THERAPY:

None.

EVIDENCE OF INJURY:

There are multiple gunshot wounds to the head, [REDACTED]
[REDACTED] The wounds are numbered for convenience and do not indicate the order in which
they were inflicted.



X-RAYS:

Films of the head and upper chest are taken.

INTERNAL EXAMINATION**SEROUS CAVITIES:**

There are no fluid collections or adhesions within the pleura, peritoneum or pericardium.

NECK ORGANS:

The thyroid gland is congested and purple. Upon sectioning, there are no focal lesions.

HEART:

The heart is 420 grams. The expected weight based on a lean body weight of 159 pounds is 360 grams. The coronary arteries arise normally and are right-sided dominant. There is no coronary artery disease. The myocardium is red, firm and without scars. The septa are intact. The foramen ovale is sealed. The left ventricular wall is concentric. The valves are thin, delicate, and unremarkable.

AORTA:

The aorta is free of fatty streaks plaques or calcifications. There is red hemolytic staining along its length.

LUNGS:

The right lung is 450 grams, and the left lung is 430 grams. The tracheobronchial tree is free of fluid, foam or obstruction. Both lungs are normally aerated. There is mild anthracotic pigment across the surfaces. Upon sectioning, there is mild pulmonary edema that exudes from the cut surfaces. There are no focal lesions.

LIVER AND GALLBLADDER:

The liver is 1,575 grams. The capsule is intact and covers a red-brown parenchyma. Upon sectioning, there are no focal lesions. The gallbladder contains 5 milliliters of yellow bile. The velvety mucosa has cholesteatosis. There are no stones in the lumen.

SPLEEN:

The spleen is 170 grams. The capsule is intact and covers firm, dark red parenchyma. The inferior margin of the spleen has a cystic lesion suggestive of a hemangioma. The white pulp is easily visualized and is unremarkable.

PANCREAS:

The pancreas has a normal tan-brown, lobulated architecture without focal lesions.

ADRENAL GLANDS:

The glands have yellow cortices and tan medullae without focal lesions.

GASTROINTESTINAL TRACT:

The tongue is [REDACTED]. The esophagus is patent. The gastroesophageal junction and gastric mucosa are autolytic. There are no rugal folds present. The stomach contains 50 milliliters of tan fluid with white food fragments. The small and large intestines are distended with gas. The appendix is present.

KIDNEYS:

The right kidney is 170 grams, and the left kidney is 175 grams. Both capsules strip with ease from each pale, smooth cortical surface. Upon bisection, the calyces are patent and free of stones or hydronephrosis.

BLADDER:

The bladder contains scant yellow urine. The mucosa is light tan and unremarkable.

GENITALIA:

The uterus, Fallopian tubes and ovaries are present. The uterus is small in size. The serosa, endometrium and myometrium are light tan and free of lesions. The Fallopian tubes are pink-purple and uninterrupted. The ovaries are boggy and upon sectioning have multiple normal follicles.

BRAIN AND MENINGES:

The brain is 1,270 grams. There is no epidural or subdural hemorrhage. There is thin, diffuse, [REDACTED] hemorrhage present. [REDACTED]

[REDACTED] Upon sectioning, the cortical ribbon is thin and even. [REDACTED]

[REDACTED]

SKULL AND SUBGALEA:

[REDACTED]

[REDACTED] subgaleal hemorrhages of [REDACTED] subgaleal hemorrhage. The scalp is [REDACTED]

RIBS/STERNUM:

The ribs and sternum are [REDACTED] and within normal limits.

VERTEBRAE:

The vertebrae are [REDACTED] and within normal limits.

PELVIS:

The pelvis is [REDACTED] and within normal limits.

EXTREMITIES:

The extremities have tattoos and scars as previously described.

[REDACTED]

LABORATORY EXAMINATION

Laboratory examinations were ordered, and the results are attached.



HAMILTON COUNTY CRIME LABORATORY
The Frank P. Cleveland, M.D. Institute of Forensic Medicine, Toxicology and Criminalistics
3159 Eden Avenue, Cincinnati, Ohio 45219-2299
Crime Laboratory 513-946-8750 Fax 513-946-8772




TOXICOLOGY REPORT

SUBJECT NAME(S): Rhoden, Dana
SUBMITTING AGENCY: Pike County Coroner

FILE #: CC16-01420
DATE REPORTED: 05/20/2016

RESULTS:



Rachel M. Hamilton

Rachel M. Hamilton
Toxicologist



Hamilton County Coroner

The Frank P. Cleveland, M.D. Institute of Forensic Medicine, Toxicology and Criminalistics
3159 Eden Avenue, Cincinnati, Ohio 45219 2299
Office: 513-946-8700 Fax: 513-946-8727




GARY RHODEN

CC16-01415


OPINION

Diagnoses:

1. Multiple gunshot wounds to the head:



4. Postmortem toxicology:



Cause of Death: It is my opinion, based on the autopsy findings and the information available to me at the time of the autopsy that the cause of death is multiple gunshot wounds to the head.

A handwritten signature in cursive script, appearing to read "K. Looman".

Karen Looman, D.O.
Chief Deputy Coroner, Forensic Pathologist
Hamilton County, Ohio

7/8/2016

Date

**POSTMORTEM EXAMINATION
OF THE BODY OF**

GARY RHODEN

A postmortem examination of the body identified by the Pike County Coroner's Office as "Gary Rhoden" is performed at the Hamilton County Coroner's Office on Sunday, April 24, 2016 at 10:20 a.m. by Dr. Karen Looman. [REDACTED]

HISTORY:

The decedent is a 37-year-old white male who was found deceased with multiple gunshot wounds to the head.

EXTERNAL EXAMINATION

GENERAL:

The body is that of a normally developed, well-nourished, adult male who is 211-1/2 pounds, 73-inches in height, and appears appropriate for the stated age. [REDACTED]

[REDACTED] The body is cool to the touch due to refrigeration. [REDACTED]

[REDACTED] The scalp hair is short, dark brown and straight. There is dark brown mustache, beard and stubble across the hair-bearing portions of the face. [REDACTED]

[REDACTED] The irides are blue. The mouth is [REDACTED] The chest has an increased anteroposterior diameter with costal margin flaring. [REDACTED]

[REDACTED] A brown mole is at [REDACTED] The spine is straight. The pelvis is stable to manipulation. The upper extremities are not edematous. There are brown paper bags covering both hands. [REDACTED]

[REDACTED] The fingernails are of medium length. The right thumb, fourth and fifth fingers have deformed thickened nails. The lower extremities have no dysmorphic features. The toenails are thickened with onychomycosis.

SCARS/TATTOOS:



There is an oblique scar [REDACTED]






MARKS OF THERAPY:

None.

EVIDENCE OF INJURY:

There are multiple gunshot wounds to the head 
 The wounds are numbered for convenience and do not indicate the order in which they were inflicted.





X-RAYS:

Films of the head and upper chest are taken.

INTERNAL EXAMINATION



SEROUS CAVITIES:

There are no fluid collections or adhesions within the pleura, peritoneum or pericardium.

NECK ORGANS:



The thyroid gland is light brown. Upon sectioning, there are no focal lesions.

HEART:

The heart is 410 grams. The coronary arteries arise normally and are right-sided dominant. There are two right conus branches present. The left anterior descending coronary artery has a proximal, focal 5-percent stenosis. The rest of the coronary arteries are free of disease. The myocardium is red and soft, without scars. Both ventricles appear mildly dilated. The valves are thin, delicate, and unremarkable.

AORTA:

The aorta has fatty streaks and red hemolytic staining along its length.

LUNGS:

The right lung is 610 grams, and the left lung is 570 grams. The tracheobronchial tree is free of fluid, foam or obstruction, and the mucosa is stained dark purple and black. Both lungs are atelectatic with dark red-black congestion. The right lung has a lingula present. There is mild anthracotic pigment across the surfaces. Upon sectioning, there is mild pulmonary edema that exudes from the cut surfaces. There are no focal lesions.

LIVER AND GALLBLADDER:

The liver is 1,590 grams. The capsule is intact and covers a red-brown parenchyma. Upon sectioning, there are no focal lesions. The gallbladder is surgically absent.

SPLEEN:

The spleen is 110 grams. The capsule is intact and covers liquefied, purple parenchyma. The white pulp is not visualized. There are no focal lesions.

PANCREAS:

The pancreas is congested and has retained its lobulated architecture. No lesions are identified.

ADRENAL GLANDS:

The glands are friable but have yellow cortices and tan medullae without focal lesions.

GASTROINTESTINAL TRACT:

The tongue is atraumatic. The esophagus is patent. The gastroesophageal junction and gastric mucosa are autolytic. There are no rugal folds present. The stomach contains 250 milliliters of green-brown fluid. The small and large intestines are distended with gas. The appendix is absent.

KIDNEYS:

The right kidney is 160 grams, and the left kidney is 115 grams. Both capsules strip with ease from each smooth but cystic cortical surface. Upon bisection, the calyces are patent and free of stones or hydronephrosis.

BLADDER:

The bladder is empty. The mucosa is light tan and unremarkable.

GENITALIA:

[REDACTED] The prostate and testicles are not examined.

BRAIN AND MENINGES:

The brain is 1,185 grams.

[REDACTED] Upon sectioning, the portions of the brain show a cortical ribbon that is thin and even.

SKULL AND SUBGALEA:

The skull has [REDACTED] fractures [REDACTED] There are [REDACTED] fractures [REDACTED]

RIBS/STERNUM:

The ribs and sternum are [REDACTED] and within normal limits.

VERTEBRAE:

The vertebrae are [REDACTED] and within normal limits.

PELVIS:

The pelvis is [REDACTED] and within normal limits.

EXTREMITIES:

The extremities have brown bags, [REDACTED] deformed fingernails, [REDACTED] as previously described.

[REDACTED]

LABORATORY EXAMINATION

Laboratory examinations were ordered, and the results are attached.




TOXICOLOGY REPORT

SUBJECT NAME(S): Rhoden, Gary
SUBMITTING AGENCY: Pike County Coroner

FILE #: CC16-01415
DATE REPORTED: 06/14/2016

RESULTS:



Robert G. Topmiller

Robert G. Topmiller
Chief of Toxicology



Hamilton County Coroner

The Frank P. Cleveland, M.D. Institute of Forensic Medicine, Toxicology and Criminalistics
3159 Eden Avenue, Cincinnati, Ohio 45219 2299
Office: 513-946-8700 Fax: 513 946-8727




HANNA RHODEN

CC16-01421

OPINION

Diagnoses:

1. Multiple gunshot wounds to the head [REDACTED]



2. Postmortem toxicology:
[REDACTED]

Cause of Death: It is my opinion, based on the autopsy findings and the information available to me at the time of the autopsy that the cause of death is multiple gunshot wounds to the head.

Handwritten signature of Karen Looman in cursive.

Karen Looman, D.O.
Chief Deputy Coroner, Forensic Pathologist
Hamilton County, Ohio

7/11/2016

Date

**POSTMORTEM EXAMINATION
OF THE BODY OF**

HANNA RHODEN

A postmortem examination of the body identified by Pike County Coroner's Office as "Hanna Rhoden" is performed at the Hamilton County Coroner's Office on Saturday, April 23, 2016 at 11:42 a.m. by Dr. Karen Looman. [REDACTED]

HISTORY:

The decedent is a 19-year-old white female who was found deceased in her home with multiple gunshot wounds.

EXTERNAL EXAMINATION

GENERAL:

The body is that of a normally developed, well-nourished, adult female who is 185-1/2 pounds, 67-inches in height, and appears appropriate for the stated age. The body is cool to the touch due to refrigeration. [REDACTED]

The scalp hair is blonde-brown and long. [REDACTED]

[REDACTED] The irides are brown. The mouth has native dentition and a small foam cap is at the lips. The chest has a normal anteroposterior diameter without costal margin flaring. [REDACTED]

palpable masses. The abdomen is slightly protuberant. There are striae around the waistline. [REDACTED]

The external genitalia are normal for an adult female. The spine is straight. The pelvis is stable to manipulation. The extremities are not edematous. There are brown paper bags on both hands. The fingernails are short. There is hair stubble along the lower extremities. On the right great toe is an identification tag within name "Hanna Rhoden".

[REDACTED]

SCARS/TATTOOS:

There is a linear scar across the anterior left chin. There are linear scars in the left axilla.


There is a [REDACTED] tattoo [REDACTED]. The [REDACTED] has [REDACTED]. The volar [REDACTED] has [REDACTED]. The left volar wrist has a design. There is a [REDACTED] around the [REDACTED].

MARKS OF THERAPY:

None.

EVIDENCE OF INJURY:

There are [REDACTED] gunshot wounds to the head. [REDACTED] The wounds are numbered for convenience and not indicate the order in which they were inflicted.



X-RAYS:

Films of the head and upper chest are taken.

INTERNAL EXAMINATION



SEROUS CAVITIES:

There is 300 milliliters of serosanguineous fluid in the right hemithorax and 200 milliliters in the left. There are no other fluid collections or adhesions within the pleural, peritoneum or pericardium.

NECK ORGANS:

[REDACTED] The thyroid gland is congested and purple. Upon sectioning, there are no focal lesions. A thymic remnant is in the anterior mediastinum.

HEART:

The heart is 325 grams. The coronary arteries arise normally and are right-sided dominant. There is no coronary artery disease. The myocardium is red, firm and without scars. The septa are intact. The foramen ovale is sealed. The left ventricular wall is concentric. The valves are thin, delicate, and unremarkable.

AORTA:

The aorta has minimal fatty streaks along its length.

LUNGS:

The right lung is 485 grams, and the left lung is 585 grams. The tracheobronchial tree is free of fluid, foam or obstruction. Both lungs are normally aerated. There is mild anthracotic pigment across the surfaces. Upon sectioning, there is mild pulmonary edema that exudes from the cut surfaces. There are no focal lesions.

LIVER AND GALLBLADDER:

The liver is 2,050 grams. The capsule is intact and covers a red-brown parenchyma. Upon sectioning, there are no focal lesions. The gallbladder contains 5 milliliters of yellow bile. There are no stones in the lumen.

SPLEEN:

The spleen is 270 grams. The capsule is intact and covers a firm, dark red parenchyma. The white pulp is easily visualized and is unremarkable.

PANCREAS:

The pancreas has a normal tan-brown, lobulated architecture without focal lesions.

ADRENAL GLANDS:

The glands have yellow cortices and tan medullae without focal lesions.

GASTROINTESTINAL TRACT:

The tongue is atraumatic. The esophagus is patent. The gastroesophageal junction has a scant amount of mucosal hemorrhage. The gastric mucosa is unremarkable with retention of the rugal folds. The stomach contains 200 milliliters of [REDACTED] The small and large intestines are distended with gas. The appendix is present.

KIDNEYS:

The right kidney is 160 grams, and the left kidney is 200 grams. Both capsules strip with ease from each smooth cortical surface. Upon bisection, the calyces are patent and free of stones or hydronephrosis.

BLADDER:

The bladder contains 5 milliliters of clear, yellow urine. The mucosa is light tan and unremarkable.

GENITALIA/MAMMARY GLANDS:

The uterus, Fallopian tubes and ovaries are present. The uterus is enlarged, as it is recently postpartum, and is 5.0 x 12.0 x 20-centimeters. The serosa is smooth. The myometrium is thickened. The endometrium has large dilated blood vessels in the wall and the surface is rough, red and raw appearing with minimal hemorrhage. [REDACTED]

[REDACTED] There is dark purple hemorrhage along the endometrial canal. The cervix is dilated. The Fallopian tubes are thin, purple and unremarkable. Both ovaries are soft, boggy and have several follicles. The ovarian vein within the left broad ligament is greatly swollen and firm with an antemortem thrombus that extends the whole length of the vessel to the attachment at the renal vein near the left calyx. There are four vessels in the cross section of the ligament and the largest diameter vessel is the ovarian vein at 1.0-centimeters wide. The right ovarian vein and artery are within normal limits. Both breasts are tense. [REDACTED]

[REDACTED] There are no lesions.

BRAIN AND MENINGES:

The brain is 1,370 grams. [REDACTED]

SKULL AND SUBGALEA:**RIBS/STERNUM:**

The ribs and sternum are [REDACTED] and within normal limits.

VERTEBRAE:

The vertebrae are [REDACTED] and within normal limits.

PELVIS:

The pelvis is [REDACTED] and within normal limits.

EXTREMITIES:

The extremities have tattoos, [REDACTED] as previously described.

[REDACTED]

LABORATORY EXAMINATION

Laboratory examinations were ordered, and the results are attached.

07/08/2016 njb



HAMILTON COUNTY CRIME LABORATORY
The Frank P. Cleveland, M.D. Institute of Forensic Medicine, Toxicology and Criminalistics
3159 Eden Avenue, Cincinnati, Ohio 45219-2299
Crime Laboratory 513-946-8750 Fax 513-946-8772




TOXICOLOGY REPORT

SUBJECT NAME(S): Rhoden, Hanna
SUBMITTING AGENCY: Pike County Coroner

FILE #: CC16-01421
DATE REPORTED: 05/20/2016

RESULTS:



Rachel M. Hamilton

Rachel M. Hamilton
Toxicologist



Hamilton County Coroner

The Frank P. Cleveland, M.D. Institute of Forensic Medicine, Toxicology and Criminalistics
3159 Eden Avenue, Cincinnati, Ohio 45219-2299
Office: 513-946-8700 Fax: 513-946-8727



KENNETH RHODEN

CC16-01422

OPINION

Diagnoses:

1. [REDACTED] gunshot wound to the head:

2. Postmortem toxicology:
[REDACTED]

Cause of Death: It is my opinion, based on the autopsy findings and the information available to me at the time of the autopsy that the cause of death is single gunshot wound to the head.

Handwritten signature of Karen Looman in cursive.

Karen Looman, D.O.
Chief Deputy Coroner, Forensic Pathologist
Hamilton County, Ohio

7/11/2016

Date

**POSTMORTEM EXAMINATION
OF THE BODY OF**

KENNETH RHODEN

A postmortem examination of the body identified by Pike County Coroner's Office as "Kenneth Rhoden" is performed at the Hamilton County Coroner's Office on Sunday, April 24, 2016 at 12:47 p.m. by Dr. Karen Looman. [REDACTED]

HISTORY:

The decedent is a 44 year old white male who was found deceased in his home with a gunshot wound to the head.

EXTERNAL EXAMINATION

GENERAL:

The body is that of a normally developed, well-nourished, adult male who is 228 pounds, 70-inches in height, and appears appropriate for the stated age. The body is cool to the touch due to refrigeration. [REDACTED]

The scalp hair is dark brown, straight and of medium length. It is a brown mustache and stubble across the hair-bearing portions of the face. [REDACTED]

[REDACTED] The iris is blue. [REDACTED] trauma.

[REDACTED] The mouth has native dentition.

The chest has a normal anteroposterior diameter without costal margin flaring. There are skin tags along the right neck. The abdomen [REDACTED] A mole is in the [REDACTED]

[REDACTED] The spine is straight. The pelvis is stable to manipulation. The extremities are not edematous. There are white paper bags on each hand. [REDACTED] of multiple lengths, some with chips. The palms of the hands [REDACTED] There are calluses inferior to each patella. The toenails are thickened and discolored. There is an identification tag on the right great toe with name "Kenneth Rhoden".

[REDACTED]

SCARS/TATTOOS:

There is a thick, linear white scar along the right clavicle. There is [REDACTED] over the right elbow.

MARKS OF THERAPY:

None.

EVIDENCE OF INJURY:

[REDACTED]


**X-RAYS:**

Films of the head and upper chest are taken.

INTERNAL EXAMINATION
**SEROUS CAVITIES:**

There are no fluid collections or adhesions within the pleura, peritoneum or pericardium.

NECK ORGANS:


The thyroid gland is tan and homogeneous upon sectioning.

HEART:

The heart is 440 grams. The coronary arteries arise normally and are right-sided dominant. The right coronary artery has a proximal, focal 5-percent stenosis. The mid left anterior descending coronary artery has a focal 50-percent stenosis. The rest of the coronary branches are free of disease. The myocardium is red, firm and without scars. Both the right and left ventricles are mildly dilated. The left ventricular wall is concentric. The valves are thin, delicate, and unremarkable.

AORTA:

The aorta has mild fatty streaks, plaques and hemolytic staining along its length.

LUNGS:

The right lung is 440 grams, and the left lung is 480 grams. The tracheobronchial tree has blood along its length. The mucosa is stained dark purple. There is no obstruction of the lumen. Both lungs are partially aerated, dark purple with congestion, and have posterior atelectasis. There is mild anthracotic pigment across the surfaces. Upon sectioning, there is mild pulmonary edema that exudes from the cut surfaces. There are no focal lesions.

LIVER AND GALLBLADDER:

The liver is 1,565 grams. The capsule is intact and covers a red-brown parenchyma. Upon sectioning, there are no focal lesions. The gallbladder is full of 0.1-centimeter round, brown stones. There is a scant amount of yellow bile present.

SPLEEN:

The spleen is 300 grams. The capsule is intact and covers liquefied, dark red-purple parenchyma. The white pulp is not visualized and there are no focal lesions.

PANCREAS:

The pancreas has autolytic changes with an orange-brown, lobulated architecture without focal lesions.

ADRENAL GLANDS:

The glands have autolytic changes and have yellow cortices and tan-brown medullae without focal lesions.

GASTROINTESTINAL TRACT:

The tongue is atraumatic. The esophagus is patent. The gastroesophageal junction and gastric mucosa are autolytic. There are rugal folds present. The stomach contains 50 milliliters of light tan fluid [REDACTED]. The small and large intestines are distended with gas. The appendix is present.

KIDNEYS:

The right kidney is 210 grams, and the left kidney is 140 grams. Both capsules strip with ease from each smooth cortical surface. Upon bisection, the calyces are patent and free of stones or hydronephrosis.

BLADDER:

The bladder contains 400 milliliters of pale, yellow urine. The mucosa is light tan and unremarkable.

GENITALIA:

[REDACTED] The prostate and testicles are not examined.

BRAIN AND MENINGES:

The brain is 1,230 grams. [REDACTED] and has a diffuse red-purple-gray discoloration of the surface. [REDACTED]

[REDACTED]

SKULL AND SUBGALEA:

[REDACTED]

[REDACTED]

RIBS/STERNUM:

The ribs and sternum are [REDACTED] and within normal limits.

VERTEBRAE:

The vertebrae are [REDACTED] and within normal limits.

PELVIS:

The pelvis is [REDACTED] and within normal limits.

EXTREMITIES:

The extremities have paper bags, a tattoo, [REDACTED] and calluses as previously described.

[REDACTED]

LABORATORY EXAMINATION

Laboratory examinations were ordered, and the results are attached.



HAMILTON COUNTY CRIME LABORATORY
The Frank P. Cleveland, M.D. Institute of Forensic Medicine, Toxicology and Criminalistics
3159 Eden Avenue, Cincinnati, Ohio 45219-2299
Crime Laboratory 513-946-8750 Fax 513-946-8772




TOXICOLOGY REPORT

SUBJECT NAME(S): Rhoden, Kenneth
SUBMITTING AGENCY: Pike County Coroner

FILE #: CC16-01422
DATE REPORTED: 05/20/2016

RESULTS:



Rachel M. Hamilton

Rachel M. Hamilton
Toxicologist



Hamilton County Coroner

The Frank P. Cleveland, M.D. Institute of Forensic Medicine, Toxicology and Criminalistics
3159 Eden Avenue, Cincinnati, Ohio 45219-2299
Office: 513-946-8700 Fax: 513-946-8727




HANNAH HAZEL GILLEY

CC16-01418

OPINION

Diagnoses:

1. Multiple gunshot wounds to the head:




[REDACTED]

[REDACTED]

2. Postmortem toxicology:

[REDACTED]

Cause of Death: It is my opinion, based on the autopsy findings and the information available to me at the time of the autopsy that the cause of death is multiple gunshot wounds to the head.



Karen Looman, D.O.
Chief Deputy Coroner, Forensic Pathologist
Hamilton County, Ohio

7/11/2016

Date

**POSTMORTEM EXAMINATION
OF THE BODY OF**

HANNAH HAZEL GILLEY

A postmortem examination of the body identified by Pike County Coroner's Office as "Hannah Gilley" is performed at the Hamilton County Coroner's Office on Saturday, April 23, 2016 at 9:22 a.m. by Dr. Karen Looman. [REDACTED]

HISTORY:

The decedent is a 20-year-old white female who was found deceased in her home with multiple gunshot wounds.

EXTERNAL EXAMINATION

GENERAL:

The body is that of a normally developed, well-nourished, adult female who is 133 pounds, 60-inches in height, and appears appropriate for the stated age. [REDACTED]

[REDACTED] The body is cool to the touch due to refrigeration. [REDACTED]

The face, anterior torso and upper extremities are covered with dried blood. The scalp hair is long and blond-brown. The ends are slightly curly. [REDACTED]

[REDACTED] The irides are brown. The mouth has native dentition. The chest has a normal anteroposterior diameter without costal margin flaring. There is a mole [REDACTED] The breasts are free of palpable masses. The abdomen is slightly distended. There is a piercing of [REDACTED] The external genitalia are normal for an adult female. The pubic hair consists of [REDACTED] The spine is straight. The pelvis is stable to manipulation. The extremities are not edematous and have no dysmorphic features. [REDACTED]

[REDACTED] On the right great toe is an identification tag with the name "Hannah Gilley" and "BCI CS0440".

[REDACTED]

SCARS/TATTOOS:

[REDACTED]

MARKS OF THERAPY:

None.

EVIDENCE OF INJURY:

There are multiple gunshot wounds to the head, [REDACTED]
[REDACTED] The gunshot wounds are numbered for convenience and do not indicate the order in which they were inflicted.



X-RAYS:

Films of the head and upper torso are taken.

INTERNAL EXAMINATION**SEROUS CAVITIES:**

There are no fluid collections or adhesions within the pleura, peritoneum or pericardium.

NECK ORGANS:

The thyroid gland is congested and purple. Upon sectioning, there are no focal lesions. A thymic remnant is in the anterior mediastinum.

HEART:

The heart is 280 grams. The coronary arteries arise normally and are right-sided dominant. There is no coronary artery disease. The myocardium is red, firm and without scars. The septa are intact. The foramen ovale is sealed. The left ventricular wall is concentric. The valves are thin, delicate, and unremarkable.

AORTA:

The aorta is free of fatty streaks, plaques or calcifications. There is red hemolytic staining present.

LUNGS:

The right lung is 450 grams, and the left lung is 340 grams. The tracheobronchial tree has a thin layer of blood along its length. There is no obstruction present. Both lungs are normally aerated. Upon sectioning, there is mild pulmonary edema that exudes from the cut surfaces. There are no focal lesions.

LIVER AND GALLBLADDER:

The liver is 1,010 grams. The capsule is intact and covers a red-brown parenchyma. Upon sectioning, there are no focal lesions. The gallbladder contains 3 milliliters of orange-yellow bile. There are no stones in the lumen.

SPLEEN:

The spleen is 130 grams. The capsule is intact and covers a firm, dark red parenchyma. The white pulp is easily visualized and is unremarkable.

PANCREAS:

It has a congested, brown, lobulated architecture without focal lesions.

ADRENAL GLANDS:

The glands are friable but have yellow cortices and tan medullae without focal lesions.

GASTROINTESTINAL TRACT:

The tongue is The esophagus is patent. The gastroesophageal junction and gastric mucosa are autolytic. There are no rugal folds present. The stomach contains 400 milliliters of tan, granular fluid. The small and large intestines are distended with gas. The appendix is present.

KIDNEYS:

The right kidney is 90 grams, and the left kidney is 120 grams. Both capsules strip with ease from each smooth cortical surface. Upon bisection, the calyces are patent and free of stones or hydronephrosis.

BLADDER:


The bladder contains 200 milliliters of clear, yellow urine. The mucosa is light tan and unremarkable.

GENTALIA/MAMMARY GLANDS:

The uterus, Fallopian tubes and ovaries are present. The uterus is slightly enlarged. There are no leiomyomata present. Upon bisection, the serosa and myometrium are pink. The endometrium has a grey lining but the surface of the endometrium is free of lesions, hemorrhage or products of conception. The cervix is unremarkable. The Fallopian tubes are purple and uninterrupted. The ovaries are soft, boggy and have normal follicles. The breasts are firm but free of lesions.

BRAIN AND MENINGES:

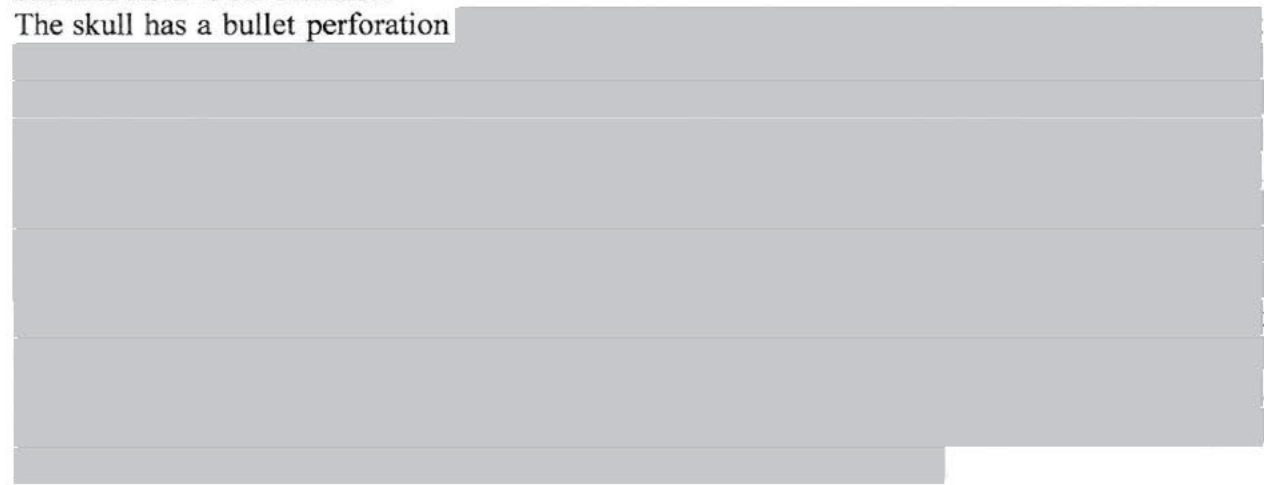
The brain is 1,220 grams.



Upon sectioning, the cortical ribbon is thin and even.

SKULL AND SUBGALEA:

The skull has a bullet perforation



RIBS/STERNUM:

The ribs and sternum are [redacted] and within normal limits.

VERTEBRAE:


The vertebrae are [redacted] and within normal limits.

PELVIS:

The pelvis is [redacted] and within normal limits.

EXTREMITIES:

The extremities have [redacted] and [redacted] as previously described.



LABORATORY EXAMINATION

Laboratory examinations were ordered, and the results are attached.

07/07/2016 njb



HAMILTON COUNTY CRIME LABORATORY
The Frank P. Cleveland, M.D. Institute of Forensic Medicine, Toxicology and Criminalistics
3159 Eden Avenue, Cincinnati, Ohio 45219-2299
Crime Laboratory 513-946-8750 Fax 513-946-8772




TOXICOLOGY REPORT

SUBJECT NAME(S): Gilley, Hannah
SUBMITTING AGENCY: Pike County Coroner

FILE #: CC16-01418
DATE REPORTED: 05/20/2016

RESULTS:



Rachel M Hamilton

Rachel M. Hamilton
Toxicologist